

DE

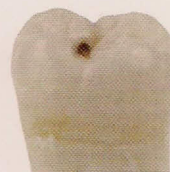DENTAL ECONOMICS®



Cultivating gratitude in the workplace
p. 74



Is social media another fad?
p. 80



The cavity in the health-care debate
p. 82

The nation's leading business journal for the profession
May 2010

Design winner
Mint Hill Dentistry
See page 16



Interview with Dr. Lawrence Kolar about dental impressions

For more on this topic, go to www.dentaleconomics.com and search using the following key words: polysulfides, polyether, impressions, alginates, Dr. Lawrence Kolar, Dr. Jeff Dalin.

Dr. Dalin: In this issue, I talk with Dr. Lawrence Kolar about impressions. This is a crucial part of what most dentists do in their practices daily. We will concentrate on the materials used when doing crowns and bridges. Let's begin with a review of the different families of materials. Dr. Kolar, would you discuss vinylpolysiloxanes (VPS) vs. vinyl polyether silicone (VPES) materials?

Dr. Kolar: First, let me state that I am not a chemist. I am a general dentist who is trying to do the best job that I can for patients with the products available on the market. I have used numerous brands of VPS materials for many years. Since they are easier to handle and don't have an unpleasant odor or taste, they are light-years beyond the polysulfides we had in the late 1970s when I was in dental school.

The problem with VPS materials is that they are not hydrophilic enough, especially in the lower molar/premolar areas. Therefore, in these cases, VPS material is technique sensitive.

In our quest for "a better mousetrap," the polyether alternative was presented as the solution to the shortcoming of the VPS materials. Now I have used polyether, and still do on occasion. But it, too, has a shortcoming. Specifically, it sets up so stiff that it is difficult to remove from the patient's mouth.

There have been advancements in the last year or so, to a "soft polyether." But several manufacturing reps whom I spoke with indicated that they would ideally recommend using even the soft polyether in a quadrant tray rather than in a full-arch tray due to its stiffness.


I know that most of my colleagues will laugh, but I insist on a full-arch tray for every impression — even for an onlay or single crown. The fact is, when you use a full-arch tray, the lab has a much easier time articulating the casts in all three dimensions. This makes for more accurate occlusal anatomy and shorter seating appointments.

I have not spoken to one lab tech who said that he or she would prefer a quadrant tray impression, nor have I had one tell me that it doesn't matter one way or the other. This presents me with a dilemma because the polyether is difficult to remove when you have a full-arch tray.

To make matters worse, imagine that you are using a custom full-arch tray, and let's say that the patient has a

missing first molar with a mesially tipped second molar. If so, you have a problem with undercuts and a tray that is even tougher to remove.

Another problem is that people with a history of periodontal surgery often have "dark triangles" in the anteriors. This is more than an esthetic challenge. It is a nightmare for removing a polyether impression that is in a custom full-arch tray.



Dr. Lawrence Kolar

So while the polyethers are good, there was a need for a "go-to" material that would result in a terrific impression — even in areas that are hard to keep dry — but has the ease of removal of the VPS that we need to use in those cases I mentioned previously.

For years, I thought that the ideal material would be a dream that could be found only in the minds of theoretical chemists. But I believe that I have found the ideal material in the VPES. I had an opportunity to try this material prior to its launch about two years ago.

The first thing I noticed was that VPES had the handling characteristics of a VPS when dispensing it in the tray, when injecting it around tooth preps in the mouth, and upon removal. In this regard, I could not distinguish between a conventional VPS and the new VPES; however, my test results showed a remarkable improvement of VPES over conventional VPS in areas that were prone to moisture control problems.

Indeed, side-by-side tests of VPES and VPS on the same patient, with custom trays and stock trays, demonstrated clinical superiority of VPES in each scenario. The degree of difference was rather striking to the point that I was stunned.

Also, I would point out that the VPES had the accuracy of polyether, even in a moist environment. Now when I realized that the VPES is as easy to remove from the mouth as the conventional VPS, I discovered that I had an ideal material in my hands. This material is clearly the "universal" material for crowns, fixed bridges, and removable partial dentures due to the combination of handling characteristics, accuracy, and moisture tolerance.

Dr. Dalin: What are the advantages and disadvantages of each of these three categories?

Dr. Kolar: In today's world, I think that conventional VPS materials are going to fall by the wayside, much as

the polysulfides have done. Yes, there are some people who continue to use polysulfides, but not many. Likewise, I think that some will continue to use VPS for most (if not all) of their cases.

But I think the real decision for the vast majority of dentists will be VPES vs. polyether. I suspect that dentists will, for the most part, fall into one of two camps: those who use VPES exclusively for fixed and removable prosthetics, and those who alternate between VPES and polyether. For those in the latter group, the VPES will be the choice whenever significant undercuts (tipped molars, periodontally involved anterior teeth, etc.) are encountered.

The disadvantage of VPS is one of obsolescence while the advantage of VPES as compared to polyether is the issue of VPES's greater versatility. Dentists tend to like a "silver bullet" for each type of product that we use not only to simplify our lives but to maintain some semblance of sanity with respect to office inventory.

Dr. Dalin: Would you discuss the steps in the process of taking impressions?

Dr. Kolar: I did a table clinic on this topic at the 2009 Chicago Dental Society's Midwinter Meeting. I was surprised by how many people came to my table and the discussions that ensued.

With this in mind, let me say that in virtually all cases I want to use a full-arch custom tray for crowns, fixed bridges, onlays, or removable prosthetics. To do this, I first need to take a stock alginate impression. This allows me to see if the patient has a hyperactive gag reflex. I prefer to learn this using alginate rather than a longer-setting VPES material.

Also, I have all of my maxillary custom trays (for fixed work) made in u-shapes rather than with palatal coverage. I use the preliminary model for construction of a putty template for the temporary too, so the study model serves more purposes than just the construction of the custom tray.

In addition, I dislike the use of retraction cord. I know there will be smart, reasonable people who disagree, but I think that packing an initial cord can disrupt the epithelial junction. I use periodontal charting to "map" my way around each sulcus when preparing a crown. I know how far down I can go without violating biological width. Once again, I can place a finish line apical to the free gingival margin even in cases in which I have a 1- to 2-mm sulcus without violating biological width.

After preparation is complete, I inject several drops of 2% lidocaine with 1:50,000 epinephrine in the papillae to help with any bleeding. After about five minutes, I apply one of several astringent agents into and around the sulcus to stop any residual bleeding that might be present. Upon rinsing out the astringent with the air/water syringe, I apply a retraction paste into the sulcus. This is an additional aid to

prevent bleeding and it also does a terrific job of retraction.

After removing the paste with the air/water syringe, I am ready to take the impression. One again, my choice is to use the custom tray, VPES (heavy body in the tray and light body injected around the sulcus and on the coronal aspects of the teeth).

When I use this combination of materials and this technique, I seldom get an unacceptable impression. So there are few retakes. Also, I seldom get a crown from the lab that has a less-than-ideal marginal fit. By eliminating shortcuts, I have essentially made life easier and more predictable.

Dr. Dalin: How do you see the role of new scanning technologies in dental practices?

Dr. Kolar: I believe that scanning technologies are the future of dental impressions; however, the high cost makes this technology prohibitive for most dentists. Also, for those who now have the technology, imagine if the machine breaks. I do not think anyone could afford a second machine to have on hand as a spare.

The point is that it will take years for this technology to be cost effective to the point that every dental office has one (or even two). Scanning technologies are analogous to concept cars. They may represent the future, but the future is years away, and the concepts have to be improved.

Meanwhile, we need to utilize and improve upon the best materials that we have available to us now. We cannot idly sit by while we wait for future technologies to be perfected and become cost effective.

Dr. Dalin: Is there anything else you would like to share?

Dr. Kolar: Let me mention that I am still excited about dentistry because I constantly try new devices and materials. I often come back to the tried and true materials that I have been using. But many times, as in the case of VPES impression materials, someone produces a "must have" material that makes dentistry easier and more enjoyable.

I would encourage people to have an open mind about these new materials and to get together with colleagues and discuss their experiences. Often, this collegiality is the best form of "continuing education" that we will experience. **DE**

Dr. Lawrence W. Kolar, DDS, has practiced in Chicago since 1982. A graduate of the University of Illinois College of Dentistry, he taught oral anatomy for 22 years in the oral biology department. He is an examiner for the Central Regional Dental Testing Service (CRDTS) and the Northeastern Regional Board of Dental Examiners (NERB). You may reach Dr. Kolar at kolardds@comcast.net.

Jeffrey B. Dalin, DDS, FADC, FAGD, FICD, practices general dentistry in St. Louis. He is a cofounder of the Give Kids A Smile program. Contact Dr. Dalin at jeff@dfdasmiles.com.